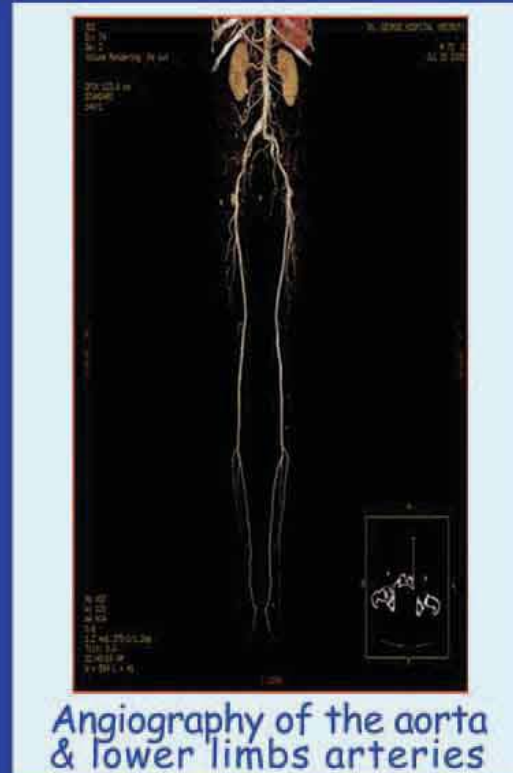
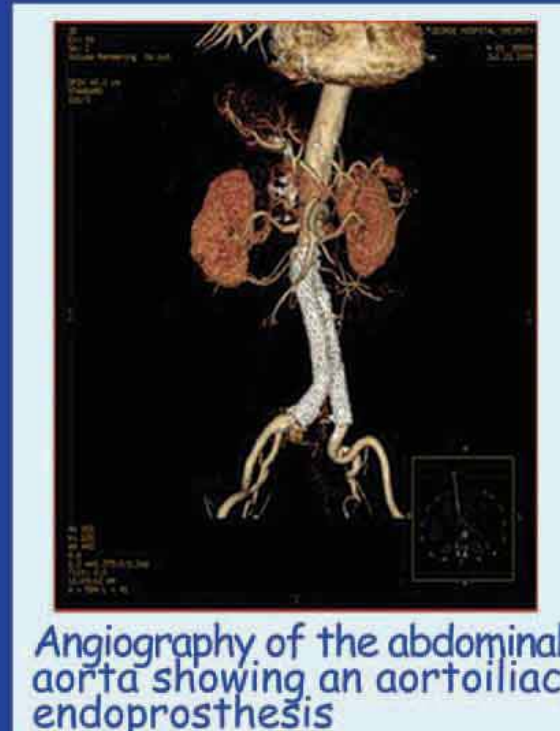




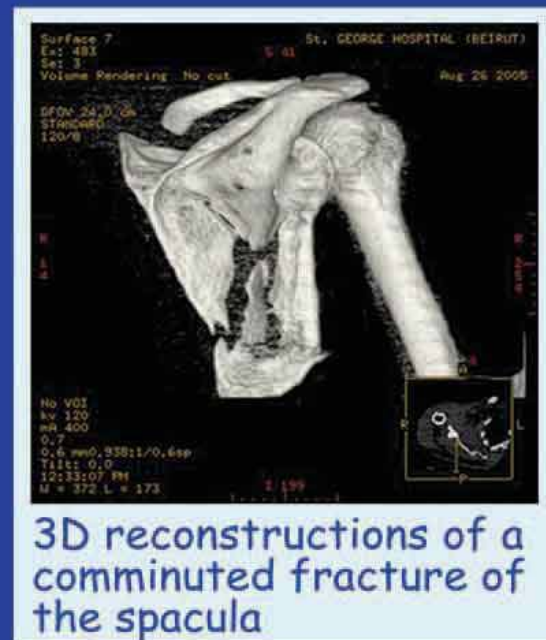
**SAINT GEORGE HOSPITAL
UNIVERSITY MEDICAL CENTER**



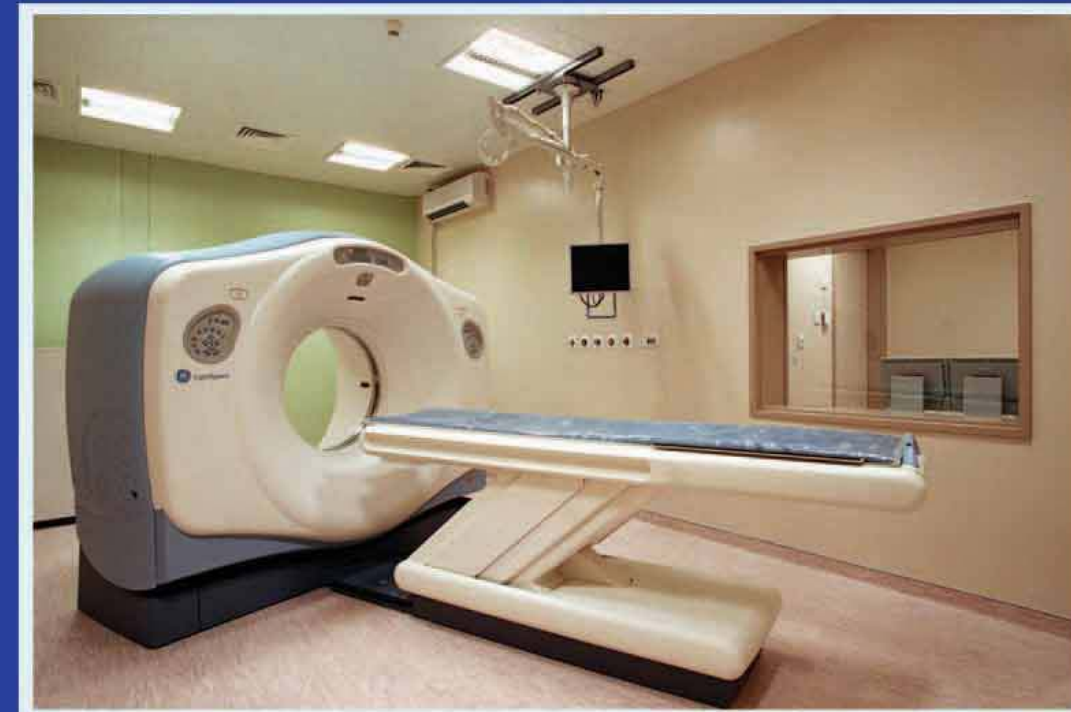Angiography of the aorta & lower limbs arteries



Angiography of the abdominal aorta showing an aortoiliac endoprosthesis



3D reconstructions of a comminuted fracture of the scapula



**GE LIGHTSPEED
16 DETECTOR CT SCAN**

For further information, please contact
Saint George Hospital University Medical Center
Diagnostic Radiology Department
Tel:01 587 000 ext: 3474-3477 or 3476

www.stgeorgehospital.org

